

Lengthening Temporalis Myoplasty for Single-Stage Smile Reconstruction in Children with Facial Paralysis

Andre Panossian, M.D.

Los Angeles, Calif.



Background: Free muscle transfer for dynamic smile reanimation in facial paralysis is not always predictable with regard to cosmesis. Hospital stays range from 5 to 7 days. Prolonged operative times, longer hospital stays, and excessive cheek bulk are associated with free flap options. Lengthening temporalis myoplasty offers single-stage smile reanimation with theoretical advantages over free tissue transfer.

Methods: From 2012 to 2014, 18 lengthening temporalis myoplasties were performed in 14 children for smile reconstruction. A retrospective chart review was completed for demographics, operative times, length of hospital stay, and perioperative complications.

Results: Fourteen consecutive patients with complete facial paralysis were included. Four patients underwent single-stage bilateral reconstruction, and 10 underwent unilateral procedures. Diagnoses included Möbius syndrome ($n = 5$), posterior cranial fossa tumors ($n = 4$), posttraumatic ($n = 2$), hemifacial microsomia ($n = 1$), and idiopathic ($n = 2$). Average patient age was 10.1 years. Average operative time was 410 minutes (499 minutes for bilateral lengthening temporalis myoplasty and 373 for unilateral lengthening temporalis myoplasty). Average length of stay was 3.3 days (4.75 days for bilateral lengthening temporalis myoplasty and 2.8 for unilateral lengthening temporalis myoplasty). Nine patients required minor revisions.

Conclusions: Lengthening temporalis myoplasty is a safe alternative to free tissue transfer for dynamic smile reconstruction in children with facial paralysis. Limited donor-site morbidity, shorter operative times, and shorter hospital stays are some benefits over free flap options. However, revisions are required frequently secondary to tendon avulsions and adhesions. (*Plast. Reconstr. Surg.* 137: 1251, 2016.)

CLINICAL QUESTION/LEVEL OF EVIDENCE: Therapeutic, IV.



Current techniques used for the correction of permanent and complete facial paralysis involve static or dynamic procedures. With the introduction of the innervated, vascularized free muscle transfer, a large jump was made in both aesthetics and function.¹ The procedure, designed to address lower facial nerve palsy, is highly successful in achieving excursion of the oral commissure and bilabial closure. The result has been an improvement in dynamic smile

reanimation. The muscle (e.g., gracilis, latissimus dorsi, biceps femoris, serratus anterior, pectoralis minor) may be staged with cross-face nerve grafting using the contralateral functioning

Disclosure: *The author has no financial interest to declare in relation to the content of this article.*

Supplemental digital content is available for this article. Direct URL citations appear in the text; simply type the URL address into any Web browser to access this content. Clickable links to the material are provided in the HTML text of this article on the *Journal's* Web site (www.PRSJournal.com).

From the Division of Plastic and Maxillofacial Surgery, Children's Hospital Los Angeles.

Received for publication May 6, 2015; accepted November 19, 2015.

Copyright © 2016 by the American Society of Plastic Surgeons

DOI: 10.1097/PRS.0000000000002009

facial nerve or connected directly to an ipsilateral donor nerve, such as the masseter nerve.²⁻⁵ The advantage of two stages is spontaneous initiation of smiling by means of the unaffected contralateral facial nerve branches. Each option carries its own set of advantages and disadvantages, extensively outlined in previous studies.

However, several persistent flaws exist when using functional free muscle transfer. First, the resulting increase in cheek bulk may be difficult to control, despite accommodation by means of lipectomy of the soft tissues. This problem may exist in either the resting state or with animation. Second, the placement of the nasolabial fold has proven challenging and can vary widely because of unpredictable changes that occur with animation. Its true placement cannot be known with certainty until reinnervation has occurred and excursion can be visualized. Third, the optimal vector of oral commissure excursion is also difficult to predict intraoperatively, making fine adjustments difficult to predict. Fourth, surgical times can be extensive and hospitalization may be as long as 5 to 7 days, often requiring admission to the intensive care unit for flap monitoring. Finally, the time to achieve excursion of the oral commissure can take between 2 and 6 months or longer for innervation to reach the transplanted muscle.

In recent years, Labbé and Huault have repopularized the temporalis myoplasty for lip reanimation.⁶ Several key refinements were made on the initial work by McLaughlin in 1949 to improve results.⁷ The “lengthening temporalis myoplasty,” as described, involved mobilizing the ipsilateral temporalis muscle while keeping the neurovascular pedicle intact. The insertion of the muscle on the coronoid is mobilized and transmitted in an antegrade fashion, deep to the zygoma toward the upper lip where it is attached to the oral commissure and upper lip.

Aside from a case series reported by Veyssi re et al., there are no other case series on this technique in the pediatric population.⁸ Recognizing the limitations of free muscle transfer for facial reanimation and the relative paucity of data of this technique in children, we describe our experience using the lengthening temporalis myoplasty in a largely pediatric population.

PATIENTS AND METHODS

Between 2012 and 2014, a total of 18 lengthening temporalis myoplasty procedures were performed in 14 consecutive patients. A retrospective chart review was performed to determine

diagnosis, laterality, and ancillary procedures performed. Patient and operative variables collected included age, sex, operative times, length of hospital stay, perioperative complications, ancillary procedures, and revisions performed. Preoperative and postoperative frontal view photographs were used to assess excursion and vector symmetry. Excursion was measured on examination preoperatively and postoperatively at the oral commissure and the mid upper lip using the ruler technique described by Manktelow et al.⁹

Surgical Technique

The surgical technique has been described previously (Fig. 1).^{6,10} Preoperative assessments of excursion of the oral commissure and vector of pull are made with the patient awake and in the upright position (Fig. 2). Markings are placed on the unaffected side, and contralateral markings are made for symmetry in the setting of unilateral facial nerve palsy. The temporalis muscle is accessed by means of a coronal incision. The zygomatic arch may be osteotomized to expose the contents of the infratemporal fossa. The temporalis tendon is identified in this space as it inserts on the coronoid process of the mandible. An oblique osteotomy releases the coronoid process with the attached temporalis tendon insertion. This can be accomplished from the coronal incision above or through the nasolabial fold incision from below. After mobilizing the temporalis muscle, the coronoid and temporalis tendon are passed as a unit through the buccal fat pad and into the cheek. A counterincision is placed carefully along the future nasolabial fold externally, if not already done for access to the coronoid process. Symmetry is determined preoperatively with the patient actively animating the lip. In the setting of bilateral facial paralysis (e.g., M bius syndrome), an arbitrary nasolabial fold incision is placed at the expected location between the skin of the upper lip and cheek. The coronoid process is grasped through this incision and gently pulled through the buccal tunnel (Fig. 3). The tendon is carefully stripped, and the bone is discarded. The temporalis tendon is then opened into a broad, flat configuration from its conical shape. A large area of insertion is achieved from the oral commissure into the upper lip, just distal to the nasolabial fold. The temporalis muscle is rotated at the expense of the posterior half to allow the tendon to pass with enough length to avoid an interpositional graft. The muscle is reanchored in its new configuration within the temporalis fossa and tested for adequate excursion. A muscle stimulator is used

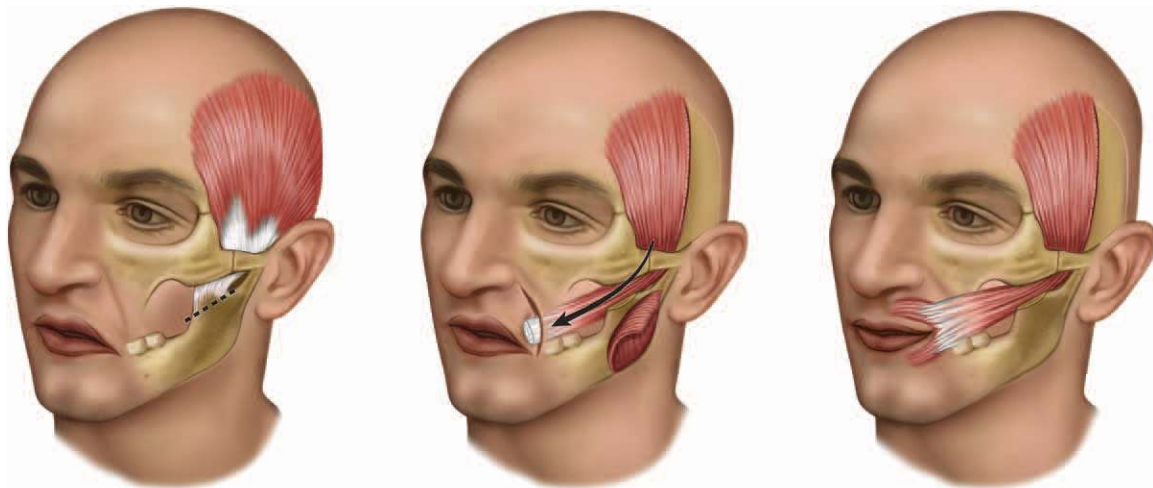


Fig. 1. Lengthening temporalis myoplasty. (Left) The coronoid process is osteotomized (dashed line) distal to the insertion of the temporalis tendon. (Center) The temporalis is mobilized posteriorly, and the tendon is freed. A tunnel is created in the buccal fat pad. The temporalis tendon is then passed through the tunnel and brought out through a nasolabial fold incision. (Right) The tendon is then stripped from the coronoid bone and unwound. It is anchored to the oral commissure and upper lip.

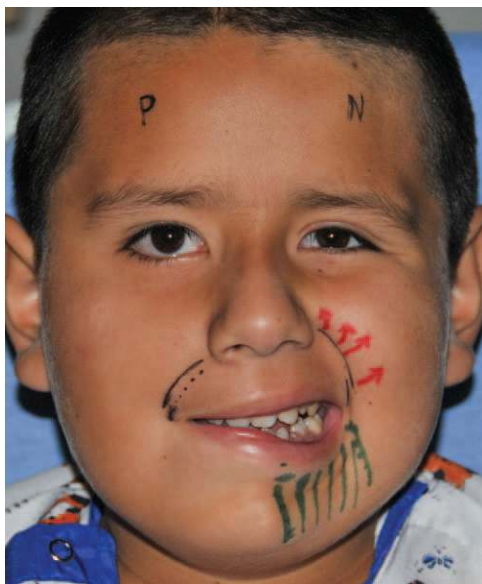

Fig. 2. Preoperative markings of the planned nasolabial fold and vector of excursion of contralateral oral commissure. In this case, contralateral lower lip depressor myectomy was planned also (green hatch marks).

to create a tetanic contraction to refine the vector of excursion at the oral commissure and reproduce movement as seen on the unaffected side. The tendon insertion is adjusted to replicate the patient's "normal" smile according to the Rubin classification. An indwelling anesthetic infusion catheter is placed along the neurovascular pedicle to avoid excessive spasm of the temporalis muscle and to provide pain relief.

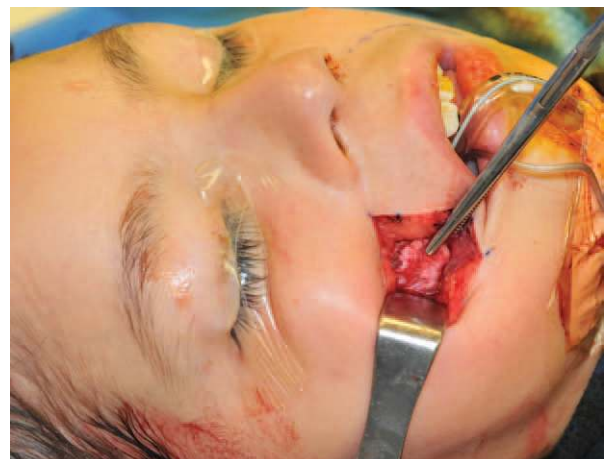

Fig. 3. The temporalis tendon, attached to the coronoid process, is directed through the buccal fat pad and delivered through the nasolabial fold incision.

Ancillary procedures include contralateral zygomaticus major/minor and risorius chemodenervation with botulinum toxin type A (Botox; Allergan, Inc., Irvine, Calif.).^{11,12} A total of 6 to 8 units of Botox (2 units per 0.1 ml of solution) is injected near the junction between these muscles and the orbicularis oris. Injection into the contralateral, active facial musculature causes relaxation of unopposed contraction and allows the temporalis muscle insertion and origin to anchor in their new position without excessive countertension. This small amount of Botox limited to the distal portions of the muscles only serves to weaken their pull on the upper lip and oral commissure without inducing lip lag on

the unaffected side. In addition, some patients subjectively demonstrating excessive contralateral lower lip depressor muscle activity underwent transbuccal myectomy to reestablish lower lip symmetry.^{13,14}

Physical therapy is started 3 weeks after surgery. Goals are to achieve greater mobility and symmetry, develop spontaneity, and improve swallowing and speech. A physical therapist initiates a biofeedback program, scar and facial massage, tendon gliding, motor learning, and a home mirror (mime) exercise program.

Anatomy

The temporalis muscle originates broadly in the temporal fossa and the temporal crest. Deep and superficial layers have been described.¹⁵ The muscle converges from its fan-like orientation to a unique three-dimensional tendon that inserts on the coronoid process of the mandible.¹⁶ As it passes deep to the zygomatic arch, there is intimate association with the masseter muscle. Fibers from the masseter can intermingle and attach to the temporalis muscle and tendon, thereby potentially limiting excursion underneath the arch. These masseter fibers can insert as far as 2 cm above the zygomatic arch onto the deep temporalis fascia.¹⁷

The temporalis is dually innervated by the anterior and posterior deep temporal nerves, arising from the anterior division of the mandibular nerve (V_3). Being a muscle of mastication, it is responsible for powerfully establishing occlusion. It is a single-vector muscle in this regard and an ideal candidate for smile reconstruction.

Its arterial supply is from the anterior and posterior deep temporal arteries, divisions of the internal maxillary artery. The vessels emerge

within the infratemporal fossa and travel with the anterior and posterior deep temporal nerves as they separate from the mandibular nerve (through the foramen ovale).

Simply disinserting the temporalis tendon from the coronoid process and stretching it toward the perioral region is usually insufficient and over-stretches the native resting length of the muscle. Tendon or fascial interposition grafts have been used to make up the difference in length.¹⁸ However, this often results in inadequate excursion. Lengthening of the temporalis tendon in lengthening temporalis myoplasty occurs at the expense of the posterior half of the temporalis muscle.¹⁹

RESULTS

A total of 18 lengthening temporalis myoplasty procedures were performed in 14 consecutive patients with complete facial paralysis over a 2-year period (Table 1). Ten patients underwent unilateral procedures, and four patients had bilateral lengthening temporalis myoplasty performed. Average patient age was 10.1 years (range, 5.4 to 17.8 years). Follow-up ranged from 10 to 34 months, with an average of 28 months. All patients demonstrated mobility of the lip along the upper lip and oral commissure, with nasolabial fold creation. Average time to animation was 2.5 weeks. Range of oral commissure excursion was between 5 and 13 mm, with an average of 8.2 mm. Smiling was activated coincidentally with biting in all patients. No interpositional fascia or tendon grafts were used.

Average operative time was 410 minutes (499 minutes for bilateral lengthening temporalis myoplasty and 373 minutes for unilateral lengthening temporalis myoplasty). Average length of stay was 3.3 days (4.75 days for bilateral lengthening

Table 1. Summary of Patient Data

Patient	Age (yr)	Sex	Diagnosis	Laterality	Follow-Up (mo)	Operative Time (min)	Length of Stay (days)	Commissure Excursion (mm)	Revision
1	5	F	Möbius syndrome	B	30	515	6	7	No
2	14	F	Möbius syndrome	R	34	337	1	5	Yes
3	12	M	Medulloblastoma	R	21	345	3	11	No
4	5	F	Idiopathic	L	21	290	2	8	Yes
5	7	M	Möbius syndrome	B	25	531	6	6	Yes
6	9	M	Möbius syndrome	B	18	478	3	6	Yes
7	10	F	Medulloblastoma	R	25	336	3	10	Yes
8	6	M	Astrocytoma	L	10	466	3	8	Yes
9	8	M	Trauma	L	24	335	3	9	Yes
10	12	F	Trauma	L	33	487	1	5	Yes
11	17	F	Hemifacial microsomia	R	21	304	4	10	No
12	8	M	Möbius syndrome	B	20	473	4	13	No
13	10	F	Medulloblastoma	L	22	399	4	11	No
14	13	F	Idiopathic	R	23	432	4	6	Yes

M, male; F, female; L, left; R, right; B, bilateral.

temporalis myoplasty and 2.8 days for unilateral lengthening temporalis myoplasty). Five patients had simultaneous contralateral depressor angularis oris myectomy performed for lower lip symmetry. One patient underwent simultaneous lagophthalmos correction, and six patients had injection of Botox into the contralateral zygomaticus major and minor, risorius, and depressor angularis oris muscles. Three patients demonstrated moderate temporal hollowing. These patients did not undergo any further correction, although fat injection was offered. Nine patients required revision of the temporalis tendon insertion site or lysis of adhesions (64 percent), and two patients required blood transfusion during the perioperative period. One patient developed a postoperative infection requiring incision and drainage.

CASE REPORTS

Case 1

A 10-year-old girl (patient 7 in Table 1) developed complete right facial paralysis following resection of a medulloblastoma (Fig. 4). With no recovery of facial nerve function 18 months later, the patient underwent a lengthening temporalis myoplasty with simultaneous contralateral lower lip depressor angularis oris and labii inferioris myectomy for balance and symmetry. The patient developed moderate temporal hollowing. She subsequently underwent revision of the tendon insertion site 3 years later. At 3 months postoperatively, she demonstrated improved excursion and symmetry of her smile. (See Video, Supplemental Digital Content 1, which demonstrates the patient in case 1, a 10-year-old girl who underwent unilateral lengthening temporalis myoplasty and subsequent revision. Preoperative and postoperative perioral function is recorded, <http://links.lww.com/PRS/B655>.)

Case 2

An 8-year-old boy with Möbius syndrome (patient 12 in Table 1) and complete bilateral facial paralysis underwent smile

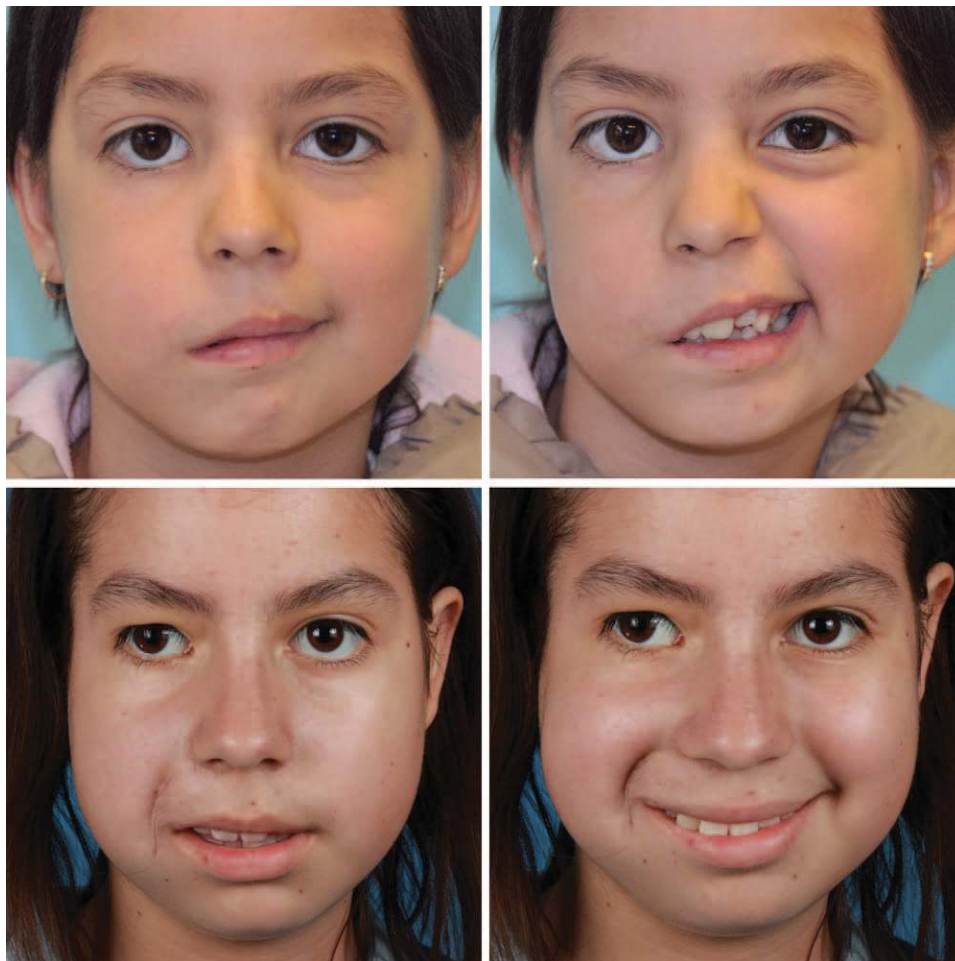
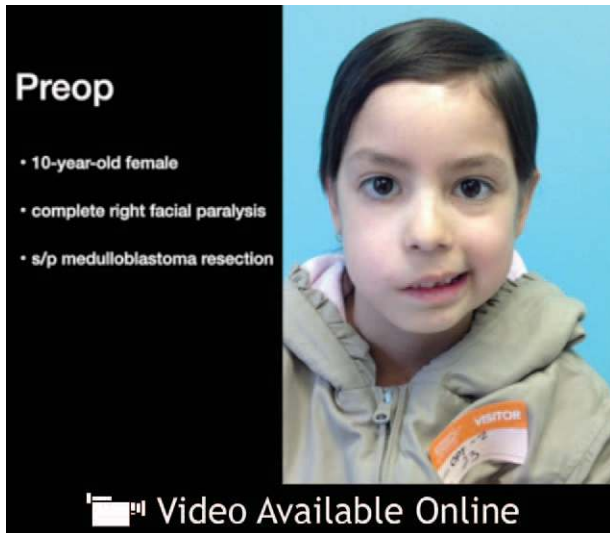
Fig. 4. Case 1 (patient 7 in Table 1). (Above) Complete right facial paralysis over 2 years after resection of a medulloblastoma. Shown preoperatively at rest and with a full-tooth smile. (Below) Postoperative appearance at 2 months after revision of the tendon insertion site. She did demonstrate moderate right temporal hollowing after the initial operation.



Video 1. Supplemental Digital Content 1 demonstrates the patient in case 1, a 10-year-old girl who underwent unilateral lengthening temporalis myoplasty and subsequent revision. Preoperative and postoperative perioral function is recorded, <http://links.lww.com/PRS/B655>.

restoration with single-stage bilateral lengthening temporalis myoplasties (Fig. 5). The patient required a 4-day hospitalization and was discharged to home with an unremarkable postoperative course. Three weeks after surgery, the patient was started on facial therapy, including biofeedback and mirror exercises. He demonstrated excellent symmetry and mobility of the smile with 13 mm of oral commissure excursion and good nasolabial fold production. (See Video, Supplemental Digital Content 2, which demonstrates postoperative perioral function following a bilateral lengthening temporalis myoplasty procedure for the patient in case 2, <http://links.lww.com/PRS/B656>.)

Case 3

A 10-year-old girl (patient 13 in Table 1) presented with a 14-month history of complete left hemifacial paralysis following resection of a medulloblastoma (Fig. 6). Given the total lack of reinnervation of the facial nerve and persistent facial asymmetry, the patient was recommended for a lengthening temporalis myoplasty for lip reanimation. She also underwent contralateral depressor angularis oris and labii inferioris myectomy for lower lip balance. The patient was hospitalized for 4 days and had an unremarkable postoperative course. She demonstrated immediate mobility of the oral commissure (11-mm excursion) with improvement of facial symmetry. She developed effortless activation of the smile within 3 weeks and required no revisions. (See Video, Supplemental Digital Content 3, which demonstrates postoperative results following unilateral lengthening temporalis myoplasty for the patient in case 3, <http://links.lww.com/PRS/B657>.)

DISCUSSION

The lengthening temporalis myoplasty is an intriguing take on an infrequently used muscle transfer for facial paralysis. By advancing the temporalis in an antegrade fashion, the temporalis

tendon achieves better elongation for upper lip and oral commissure attachment without the need for intervening grafts. The vector of excursion is optimal for smile restoration. There are numerous potential benefits to using lengthening temporalis myoplasty for smile reanimation over vascularized free muscle transfers such as the gracilis. First, by eliminating the microsurgical component, operative time is shortened substantially. There is no secondary donor site requiring healing, and postoperative vascular compromise is not a concern. Also, there is no requirement for postoperative intensive care unit stay or prolonged hospitalization. It is even conceivable that lengthening temporalis myoplasty can be performed on an outpatient basis in selected patients. Second, the actuating temporalis muscle is not denervated; therefore, the time to animation is negligible over free tissue transfer, which requires time for nerve regeneration. This has an impact on immediate results and on initiating facial therapy. Third, the problem of excessive cheek bulk common to free muscle transfers is avoided because of the trajectory of the temporalis tendon deep to the zygomatic arch and within the buccal fat pad. Fourth, smile reconstruction can be tested intraoperatively by direct muscle stimulation and adjusted as necessary.^{6,20,21} This is an important advantage of lengthening temporalis myoplasty over free muscle transfer. By stimulating the muscle, the degree of expected postoperative movement is predicted along with vector of excursion and accurate placement of anchoring sutures. Fifth, placement of a nasolabial incision is helpful in defining the location of the nasolabial fold, exactly at the junction of the upper lip and cheek skin.²² It also aids in the adjustment of anchoring sutures for the temporalis tendon insertion. In some instances, coronoidectomy can be performed through this incision without the need for zygomatic arch osteotomy. Lastly, by shortening the surgical time, ancillary procedures can be performed to help improve global facial symmetry. Contralateral lower lip depressor myectomy or Botox injection, ipsilateral lagophthalmos correction, ipsilateral brow elevation, and midface lift can all be performed in a single, comprehensive operative effort.

There is one large disadvantage noted. Less than ideal excursion resulted from tendon avulsion from the insertion site and/or muscle adhesions within the cheek and subzygomatic region. In our study, 64 percent of patients required revision surgery, including tenolysis and readvancement of the temporalis tendon. This occurred

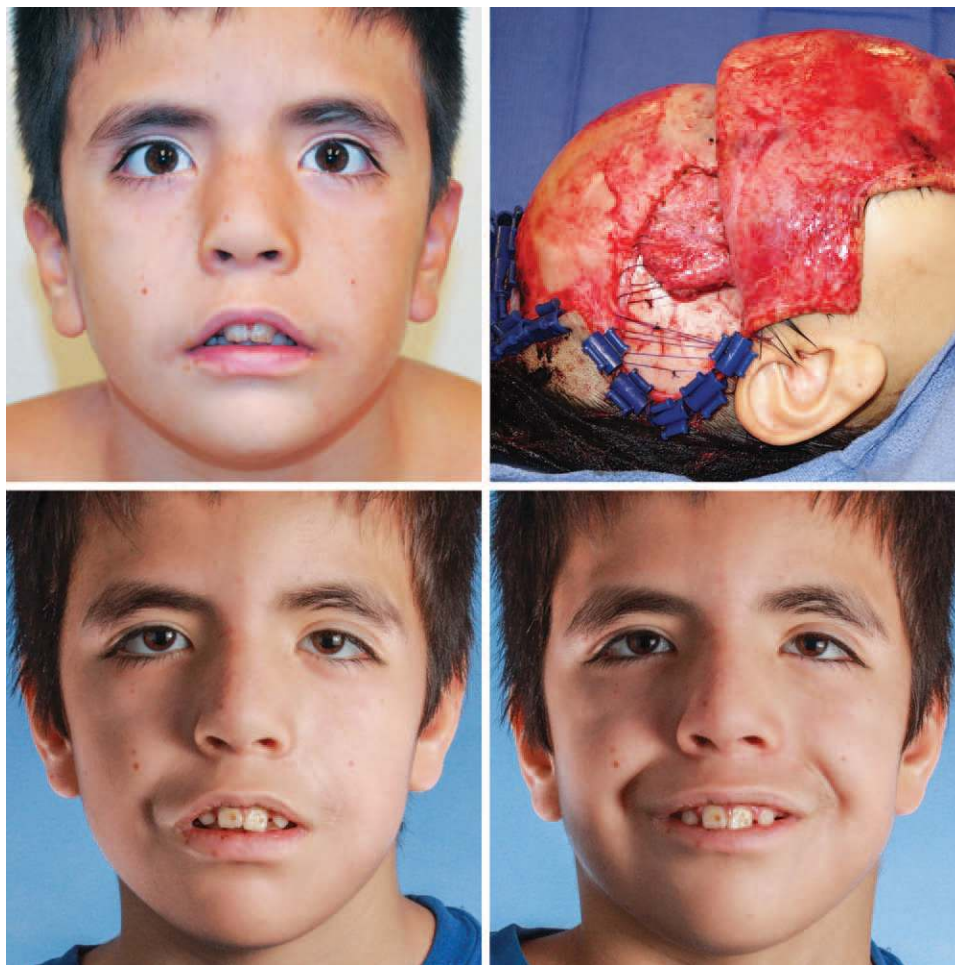

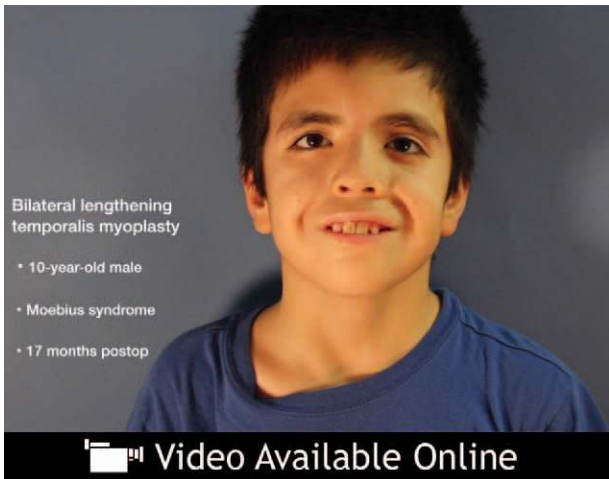Fig. 5. Case 2. (Above, left) Bilateral facial paralysis in a Möbius syndrome patient (patient 12 in Table 1) during attempted smile. (Above, right) Reorientation and fixation of temporalis origin following bilateral lengthening temporalis myoplasty. (Below) Postoperative facial motion at 17 months.

despite measures to reduce tension on the temporalis muscle, including use of Botox on contralateral facial musculature and placement of an indwelling local anesthetic infuser catheter near the neurovascular pedicle. This is admittedly a rather high rate. However, revisions were all performed on an outpatient basis through the nasolabial fold incision only. In older children and adults, it is conceivable that this type of revision can be performed under local anesthesia. Nonetheless, as experience with lengthening temporalis myoplasty evolves, refinements in technique may eliminate this problem or reduce it significantly.

Another disadvantage is one that is common also to free gracilis muscle transfers that use the masseter nerve for stimulation. Given that the temporalis muscle is supplied by the trigeminal nerve, it lacks an element of spontaneity. Muscle retraining is a requirement and may not occur for

months to years. However, other reports have indicated a return of spontaneous or effortless smile activation in the majority of patients.^{23,24} These studies reiterate the existence of cortical plasticity and reorganization of the motor system to functionally relevant muscles.^{25,26}

Next, although placement of a nasolabial fold incision is helpful in defining the desired location on the paralyzed side and for inseting the temporalis tendon, the presence of an external incision is not ideal. Some studies have suggested that subdermal plication more accurately defines this structure by means of a facial skin flap.²⁷⁻²⁹ The difficulty lies in reproducibility. Also, the presence of a nasolabial fold incision allows easy access for revision surgery when necessary, without the need to elevate large facial skin flaps. Although a buccal incision is an attractive option in accessing the temporalis tendon, it still proves challenging in the precise placement of tendon-anchoring



Video 2. Supplemental Digital Content 2 demonstrates postoperative perioral function following a bilateral lengthening temporalis myoplasty procedure for the patient in case 2 (patient 12 in Table 1). <http://links.lww.com/PRS/B656>.

sutures in the perioral region required for recreation of the nasolabial fold.

Also, three patients demonstrated moderate temporal contour deficit several months postoperatively. There are three potential sources for this problem. As part of the learning curve, earlier cases were performed with complete mobilization of the temporalis within the temporal fossa as opposed to only the posterior half. The visual portion of the temporal fossa is the anterior portion. Despite resecuring the muscle to a cuff of strong fascia along the anterior temporal crest, thinning of the overlying tissues was observed. Alternatively, or synergistically, elevation of the coronal flap over the zygomatic arch must include a fat pad that resides on the deep temporalis fascia. This was inadvertently omitted in early efforts. The fat pad must then be excised if left on top of the temporalis, because it interferes with



Fig. 6. Case 3 (patient 13 in table 1). (Above, left) Complete left facial paralysis nearly 3 years after resection of a medulloblastoma. Preoperative markings and asymmetric smile are shown. (Above, right) Postoperative appearance at 7 months after lengthening temporalis myoplasty. (Below) Oblique view of postoperative smile activation.



Video 3. Supplemental Digital Content 3 demonstrates postoperative results following unilateral lengthening temporalis myoplasty for the patient in case 3, <http://links.lww.com/PRS/B657>.

elongation of the tendon in the subzygomatic region as it passes into the buccal space. Finally, zygomatic arch osteotomy itself may result in atrophy of the osteotomized segment. This final point is difficult to prove without further studies using postoperative computed tomography. Unlike cranial vault remodeling or fronto-orbital advancement where true temporal hollowing occurs as a result of a bony phenomenon, temporal contour deformities in lengthening temporalis myoplasty are related to soft-tissue changes.^{30,31}

Other variations of temporalis tendon transfer have been used with varying degrees of success.^{32–36} The orthodromic temporalis tendon transfer uses a single incision to mobilize only the coronoid process and attached tendon. No additional lengthening is reported. Simple transfer of the tendon to the oral commissure from the coronoid process has proven to be difficult and frequently requires an interpositional tendon or fascial graft.^{37,38} Results with interpositional grafting have been mediocre and difficult to reproduce. In lengthening temporalis myoplasty, by mobilizing the temporalis muscle and allowing it to advance or lengthen at the expense of its posterior segment, the tendon is able to achieve sufficient length to reach the upper lip and oral commissure without a tendon graft. We did observe this advantage. An intervening, nonvascularized graft has the disadvantage of succumbing to scarring and weakening over time, both of which can adversely affect outcomes.

The more traditional temporalis turnover flap predates microvascular functional muscle transfers.^{22,39–41} In this procedure, the entire muscle or a portion of it is turned over the zygomatic arch and stretched toward the perioral region. Many disadvantages make this a less desirable option. First, excessive bulk over the zygomatic arch can be unsightly. Second, the length of muscle from the top of the origin of the muscle to the pivot point above the arch is frequently too short to reach the corner of the mouth. This requires the use of a nonvascularized interpositional fascia or tendon graft, which frequently results in adhesions, weakening, and loss of movement. In addition, a secondary donor site is required. None of the patients in this study required an interpositional graft. Third, if the entire muscle is used, there is a significant degree of temporal hollowing requiring secondary procedures to fill.

Other single-stage options for lip reanimation are available, including free latissimus dorsi, rectus abdominis, and serratus anterior flaps.^{42–47} These flap options promise greater spontaneity by means of coaptation with the contralateral functioning facial nerve. Proposed initially by Harii, the segmental latissimus dorsi flap involves harvesting a long length of thoracodorsal nerve that will then need to regenerate into the implanted muscle.⁴⁸ Although some studies report favorable results, others highlight inconsistent results and a high failure rate as described by weak or no contraction. In addition, there are a wide range of reported latent periods until reinnervation occurred, from 3 to 16 months. In the pursuit of true spontaneity of smile, the two-stage cross-face nerve graft followed by free muscle graft is perhaps a better option. The length of time to reinnervation of the transplanted muscle is critical. By allowing the nerve impulse to regenerate along the cross-face nerve graft, the distance required for secondary innervation into the functional muscle is effectively shortened.

As with gracilis muscle transfer for lip reanimation, lengthening temporalis myoplasty addresses only oral commissure and upper lip elevation as it occurs with smiling. The procedure by itself does not address other sequelae of facial paralysis, such as the lack of ipsilateral lower lip depression. However, the shortened operative time offered by lengthening temporalis myoplasty allows simultaneous correction of several facial asymmetries, including contralateral lower lip depressor myectomy, lagophthalmos correction, and contralateral frontalis myectomy.⁴⁹ In addition,

chemodenervation of overactive contralateral facial musculature with Botox can be performed quickly and easily, without any discomfort.

CONCLUSIONS

The lengthening temporalis myoplasty is an excellent and reproducible alternative to free vascularized muscle transfer for smile reanimation in facial paralysis. Some of the advantages include reduced operative time and hospital stay, quicker time to activation, and improved cheek contour without excess bulk. The disadvantages include a steep learning curve and high revision rate secondary to problems at the temporalis tendon insertion site. We observed greater predictability of smile reanimation with increased experience with the technique. Modifications and refinements can conceivably improve results further.

Andre Panossian, M.D.

9033 Wilshire Boulevard, Suite 200
Beverly Hills, Calif. 90211
drpanossian@drpanossian.com

PATIENT CONSENT

Parents or guardians provided written consent for the use of patients' images.

REFERENCES

- Zuker RM. Microvascular management of facial palsy. In: *Current Therapy in Plastic and Reconstructive Surgery*. Boca Raton, Fla: CRC Press; 1989:157–162.
- Manktelow RT, Tomat LR, Zuker RM, Chang M. Smile reconstruction in adults with free muscle transfer innervated by the masseter motor nerve: Effectiveness and cerebral adaptation. *Plast Reconstr Surg*. 2006;118:885–899.
- Manktelow RT, Manktelow RT. Cross-facial nerve graft: The long and short graft. The first stage for microneurovascular muscle transfer. *Oper Tech Plast Reconstr Surg*. 1999;6:174–179.
- Fattah A, Borschel GH, Manktelow RT, Bezuhly M, Zuker RM. Facial palsy and reconstruction. *Plast Reconstr Surg*. 2012;129:340e–352e.
- Bae YC, Zuker RM, Manktelow RT, Wade S. A comparison of commissure excursion following gracilis muscle transplantation for facial paralysis using a cross-face nerve graft versus the motor nerve to the masseter nerve. *Plast Reconstr Surg*. 2006;117:2407–2413.
- Labbé D, Huault M. Lengthening temporalis myoplasty and lip reanimation. *Plast Reconstr Surg*. 2000;105:1289–1297; discussion 1298.
- McLaughlin CR. Surgical support in permanent facial paralysis. *Plast Reconstr Surg (1946)* 1953;11:302–314.
- Veyssière A, Labbé D, Bénateau H. Lengthening temporalis myoplasty and facial paralysis from birth. *J Plast Reconstr Aesthet Surg*. 2015;68:312–320.
- Manktelow RT, Zuker RM, Tomat LR. Facial paralysis measurement with a handheld ruler. *Plast Reconstr Surg*. 2008;121:435–442.
- Labbé D. Lengthening temporalis myoplasty V.2. and lip reanimation (in French). *Ann Chir Plast Esthet*. 2009;54:571–576.
- Kim J. Contralateral botulinum toxin injection to improve facial asymmetry after acute facial paralysis. *Otol Neurotol*. 2013;34:319–324.
- Clark RP, Berris CE. Botulinum toxin: A treatment for facial asymmetry caused by facial nerve paralysis. *Plast Reconstr Surg*. 1989;84:353–355.
- Labbé D, Bénichou L, Iodice A, Giot JP. Depressor anguli oris sign (DAO) in facial paresis: How to search it and release the smile (technical note) (in French). *Ann Chir Plast Esthet*. 2012;57:281–285.
- Hussain G, Manktelow RT, Tomat LR. Depressor labii inferioris resection: An effective treatment for marginal mandibular nerve paralysis. *Br J Plast Surg*. 2004;57:502–510.
- Lee JY, Kim JN, Kim SH, et al. Anatomical verification and designation of the superficial layer of the temporalis muscle. *Clin Anat*. 2012;25:176–181.
- Bénateau H, Alix T, Labbé D, Elissalde JM, Salamé E. Anatomic study of the tendinous insertion lamina of the temporalis muscle. *Surg Radiol Anat*. 2004;26:281–284.
- Guerreschi P, Gahagnon T, Vacher C, Drizenko A, Francke JP, Labbe D. Masseter muscle termination over the deep surface of the temporal fascia: Look out the wrong path. *Surg Radiol Anat*. 2011;33:863–868.
- Brown JB. The utilization of the temporal muscle and fascia in facial paralysis. *Ann Surg*. 1939;109:1016–1023.
- Martín LP, Otero TG, Gallo JA, Pérez SM, García MB. Mioplastia de elongación de músculo temporal para rehabilitación de parálisis hemifacial. *Rev Esp Cir Oral Maxilofacial* 2011;33:35–39.
- Har-Shai Y, Gil T, Metanes I, Labbé D. Intraoperative muscle electrical stimulation for accurate positioning of the temporalis muscle tendon during dynamic, one-stage lengthening temporalis myoplasty for facial and lip reanimation. *Plast Reconstr Surg*. 2010;126:118–125.
- Har-Shai Y, Metanes I, Badarny S, et al. Lengthening temporalis myoplasty for facial palsy reanimation. *Isr Med Assoc J*. 2007;9:123–124.
- Baker DC, Conley J. Regional muscle transposition for rehabilitation of the paralyzed face. *Clin Plast Surg*. 1979;6:317–331.
- Garmi R, Labbé D, Coskun O, Compère JF, Bénateau H. Lengthening temporalis myoplasty and brain plasticity: A functional magnetic resonance imaging study. *Ann Chir Plast Esthet*. 2013;58:271–276.
- Blanchin T, Martin F, Labbe D. Lengthening temporalis myoplasty: A new approach to facial rehabilitation with the “mirror-effect” method (in French). *Ann Chir Plast Esthet*. 2013;58:632–637.
- Manduch M, Bezuhly M, Anastakis DJ, Crawley AP, Mikulis DJ. Serial fMRI of adaptive changes in primary sensorimotor cortex following thumb reconstruction. *Neurology* 2002;59:1278–1281.
- Chen R, Anastakis DJ, Haywood CT, Mikulis DJ, Manktelow RT. Plasticity of the human motor system following muscle reconstruction: A magnetic stimulation and functional magnetic resonance imaging study. *Clin Neurophysiol*. 2003;114:2434–2446.
- Bhama PK, Park JG, Shanley K, Hadlock TA. Refinements in nasolabial fold reconstruction for facial paralysis. *Laryngoscope* 2014;124:2687–2692.
- Zhang L, Tang MY, Jin R, et al. Classification of nasolabial folds in Asians and the corresponding surgical approaches: By Shanghai 9th People's Hospital. *J Plast Reconstr Aesthet Surg*. 2015;68:914–919.
- Rubin LR, Mishriki Y, Lee G. Anatomy of the nasolabial fold: The keystone of the smiling mechanism. *Plast Reconstr Surg*. 1989;83:1–10.

30. Steinbacher DM, Wink J, Bartlett SP. Temporal hollowing following surgical correction of unicoronal synostosis. *Plast Reconstr Surg*. 2011;128:231–240.
31. Matic DB, Kim S. Temporal hollowing following coronal incision: A prospective, randomized, controlled trial. *Plast Reconstr Surg*. 2008;121:379e–385e.
32. Parker NP, Eisler LS, Dresner HS, Walsh WE. Orthodromic temporalis tendon transfer: Anatomical considerations. *Arch Facial Plast Surg*. 2012;14:39–44.
33. Griffin GR, Kim JC. Orthodromic temporalis tendon transfer. *Oper Tech Otolaryngol Head Neck Surg*. 2012;23:253–257.
34. Cannady SB, Rosenthal EL, Knott PD, Fritz M, Wax MK. Free tissue transfer for head and neck reconstruction: A contemporary review. *JAMA Facial Plast Surg*. 2014;16:367–373.
35. Byrne PJ, Kim M, Boahene K, Millar J, Moe K. Temporalis tendon transfer as part of a comprehensive approach to facial reanimation. *Arch Facial Plast Surg*. 2007;9:234–241.
36. Boahene KD, Farrag TY, Ishii L, Byrne PJ. Minimally invasive temporalis tendon transposition. *Arch Facial Plast Surg*. 2011;13:8–13.
37. Aum JH, Kang DH, Oh SA, Gu JH. Orthodromic transfer of the temporalis muscle in incomplete facial nerve palsy. *Arch Plast Surg*. 2013;40:348–352.
38. May M, Drucker C. Temporalis muscle for facial reanimation: A 13-year experience with 224 procedures. *Arch Otolaryngol Head Neck Surg*. 1993;119:378–382; discussion 383.
39. Mathog RH, Ragab MA. Temporalis muscle-galea flap in facial reanimation. *Arch Otolaryngol*. 1985;111:168–173.
40. May M. Muscle transposition for facial reanimation: Indications and results. *Arch Otolaryngol*. 1984;110:184–189.
41. Cheney ML, McKenna MJ, Megerian CA, Ojemann RG. Early temporalis muscle transposition for the management of facial paralysis. *Laryngoscope*. 1995;105:993–1000.
42. Wei W, Zuoliang Q, Xiaoxi L, et al. Free split and segmental latissimus dorsi muscle transfer in one stage for facial reanimation. *Plast Reconstr Surg*. 1999;103:473–480; discussion 481.
43. Harii K, Asato H, Yoshimura K, Sugawara Y, Nakatsuka T, Ueda K. One-stage transfer of the latissimus dorsi muscle for reanimation of a paralyzed face: A new alternative. *Plast Reconstr Surg*. 1998;102:941–951.
44. Asato H, Harii K, Takushima A. Smile reconstruction using one-stage transfer of the latissimus dorsi muscle. *Oper Tech Plast Reconstr Surg*. 2006;6:197–203.
45. Sajjadian A, Song AY, Khorsandi CA, et al. One-stage reanimation of the paralyzed face using the rectus abdominis neurovascular free flap. *Plast Reconstr Surg*. 2006;117:1553–1559.
46. Bartlett SP. Smile reconstruction using the serratus anterior muscle. *Oper Tech Plast Reconstr Surg*. 1999;6:190–196.
47. Takushima A, Harii K, Asato H, Ueda K, Yamada A. Neurovascular free-muscle transfer for the treatment of established facial paralysis following ablative surgery in the parotid region. *Plast Reconstr Surg*. 2004;113:1563–1572.
48. Harii K. Microneurovascular free muscle transplantation for reanimation of facial paralysis. *Clin Plast Surg*. 1979;6:361–375.
49. Labbé D, Bussu F, Iodice A. A comprehensive approach to long-standing facial paralysis based on lengthening temporalis myoplasty. *Acta Otorhinolaryngol Ital*. 2012;32:145–153.